

Soft tissue changes in patients with Class II division 1 malocclusions treated using Twin Block appliances: finite-element scaling analysis

G. D. Singh* and W. J. Clark**

*School of Medicine, University of Puerto Rico, San Juan, USA and **Fife, UK

SUMMARY To determine changes in soft tissue profile in patients with Class II division 1 malocclusions treated with Twin Block appliances (TBA), 99 pairs of lateral cephalographs were traced and 25 soft tissue landmarks digitized. Procrustes superimposition was used to generate average soft tissue profiles scaled to an equivalent size.

Statistical differences between prepubertal, pre- and post-treatment profiles were found using ANOVA ($P < 0.001$). Similarly, significant differences were found between adolescent, pre- and post-treatment profiles ($P < 0.001$). Using a colour-coded finite element scaling analysis (FESA) programme to localize size change, male prepubertal post-treatment configurations revealed local increases in size at the labiomental groove ($\approx 25\%$) with negative allometry (size-related form change $\approx 5\%$) in the labial and symphyseal regions. For the female prepubertal post-treatment configuration, local increases in size were conspicuous also at the labiomental groove ($\approx 6\%$). Male adolescent post-treatment configurations revealed increases in size in the nasal, mental, and labiomental groove regions ($\approx 18\%$) with negative allometries associated with the upper and lower lips ($\approx 20\%$). For the female adolescent post-treatment configuration, the labial fissure showed an increase in size ($\approx 17\%$), whereas the upper and lower lips and symphyseal region exhibited negative allometries ($\approx 5\text{--}15\%$). For shape change, all soft tissue post-treatment configurations were highly isotropic (uniform shape change) over the entire facial nodal mesh except in the areas of the labiomental region and the labial fissure. Thus, in children and adolescents treated for Class II malocclusions a less pronounced labiomental groove is associated with using TBAs, which may provide a more effective anterior lip seal.

Introduction

There is some evidence that various physical, psychological, and social factors affect perceptual judgments related to the development and maintenance of self-image, including perceptions of dentofacial attractiveness (Giddon, 1995). Indeed, physical attractiveness plays a major role in the social interaction among individuals (Jacobson, 1984). It has been demonstrated that three-dimensional (3D) facial characteristics differ between females on the basis of aesthetics (Ferrario *et al.*, 1995a), and it has been suggested that facial and dental aesthetics should be clinically evaluated (Al Yami *et al.*, 1998), particularly as skeletal Class II patients have a narrower face and nasomaxillary complex, as well as mandibular deficiency (Moss *et al.*, 1994). In addition, Angle Class II children have an increased facial convexity and a less prominent mandibular soft tissue complex compared with children with a normal occlusion (Ferrario *et al.*, 1994). Furthermore, quantitative evaluation of soft tissue size and shape during facial growth reveals that the facial soft tissues are influenced to some extent by skeletal Class (Ferrario and Sforza, 1997a), as well as age (Foley and Duncan, 1997) and sex (Blanchette *et al.*, 1996). Indeed,

most soft tissue landmarks show a progressive modification from birth to early adulthood (Ferrario *et al.*, 1997a). Therefore, analysis of the soft tissues is crucial in orthodontic treatment planning as the soft tissue facial matrix may limit therapeutic intervention (Ackerman and Proffit, 1997).

Aside from aesthetic considerations, oral functions such as mastication and swallowing require an effective anterior oral seal, which may be inadequate in Class II subjects. Lip competence may be assisted by soft tissue improvements, which have been reported to occur following Twin Block appliance (TBA) treatment (Clark, 1982). The main purpose of the TBA is to advance the mandible (Rondeau, 1996), but the response of the soft tissues to functional appliances (such as the TBA) is far from being fully understood. Nevertheless, a lip seal may be obtained after completion of TBA treatment, and TBA treatment may concomitantly produce improvements in facial appearance (Clark, 1988). In Class II subjects, growth changes reduce facial convexity, and these improvements are claimed to be maintained in the TBA post-treatment phase. In an earlier investigation, Morris *et al.* (1998) reported significant soft tissue changes in children following TBA treatment, but that

particular study did not employ geometric morphometrics even though a 3D laser scanning system was able to detect small changes in soft tissue facial form. Therefore, the aim of the present study was to test the null hypothesis that no improvements in facial profile are associated with TBA treatment. Rejection of the null hypothesis will enable the localization of changes in the soft tissue matrices to be demonstrated using finite element scaling analysis (FESA).

Subjects, materials and methods

After obtaining consent, pre- and post-treatment, lateral cephalographs of 46 consecutive children between 9 and 11 years of age with Angle's Class II division 1 malocclusions were retrieved from an orthodontic practice. A further 53 pairs of pre- and post-treatment cephalographs of adolescents aged 12–14 years with a similar Class II relationship were also obtained. All the subjects in the study were consecutively enrolled into treatment; there was no selection based on success of treatment, availability of records, or co-operation with the appliance. In addition, sample selection and analyses were performed on a blind basis. The total sample comprised 44 Scottish males and 55 females. Inclusion criteria included a large overjet (≥ 7 mm) and a distal occlusion related to a moderate to severe Class II skeletal relationship, treated consecutively by the same orthodontist (WJC) using TBAs. Thus, the clinician's criteria for using TBAs were moderate Class II division 1 patients with an overjet of at least 7 mm but with average to increased vertical proportions. Exclusion criteria for sample selection were a history of previous orthodontic treatment, facial trauma requiring hospital attendance, and congenital maxillofacial deformity.

The 44 males and 55 females were divided into four groups based on age and sex. The first group comprised 16 prepubertal males with a mean age of 10.2 ± 0.9 years at the beginning of treatment, and a mean treatment time of 13.6 ± 4.0 months. The second group comprised 28 adolescent males with a mean age of 12.6 ± 0.9 years and a mean treatment time of 20.1 ± 7.7 months. The third group comprised 30 prepubertal females with a mean age of 10.8 ± 1.4 years and a mean treatment time of 12.3 ± 1.4 months. The fourth group comprised 25 adolescent females with a mean age of 12.2 ± 0.7 years and a mean treatment time of 22.3 ± 6.7 months. The chronological age was assumed to match developmental age in this study, as carpal ages were unavailable.

In all cases the TBAs consisted of standard mandibular and maxillary bite blocks with inclined edges, meeting at an interlocking angle to induce occlusal forces that guided growth of the dental arches. It was presumed that when all lateral cephalographs were taken, the central X-ray passed along the transmeatal axis while the teeth were in occlusion. The magnification of each

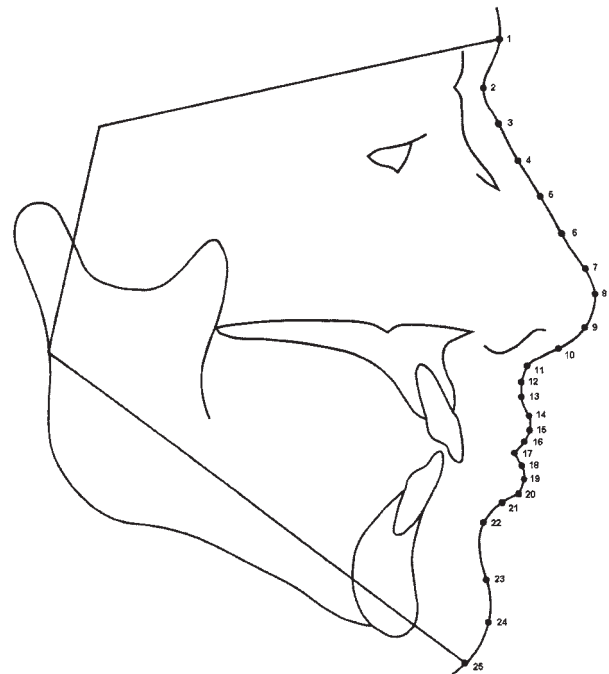


Figure 1 Tracing of lateral cephalograph indicating the homologous, soft tissue landmarks that were digitized to encompass the lateral facial profile, permitting the construction of mean soft tissue matrices studied. 1. Soft Glabella, most anterior point above Nasion on the forehead. 2. Soft Nasion, deepest point on the Nasion saddle. 3. Soft tissue point midway between Epinasale and soft Nasion. 4. Epinasale, soft tissue point opposite the inferior aspect of nasal bone. 5. Defining curvature of the nose inferior to Epinasale. 6. Defining curvature of the nose inferior to the previous point. 7. Defining curvature of the nose inferior to the previous point and superior to soft Rhinion. 8. Soft Rhinion, most anterior point on the tip of the nose on the aesthetic plane. 9. Soft tissue point most antero-superior between soft Rhinion and labio-nasal junction. 10. Soft tissue point most antero-inferior between soft Rhinion and labio-nasal junction. 11. Labio-nasal junction, point where nose and upper lip meet. 12. Soft tissue A, innermost point on the curve on the upper lip. 13. Defining curvature between soft tissue A and Labial Superioris. 14. Labial Superioris, anterior-most point on the upper lip. 15. Soft tissue point most antero-superior between Labial Superioris and Embrasure. 16. Soft tissue point most antero-inferior between Labial Superioris and Embrasure. 17. Embrasure, most anterior point where upper lip and lower lip meet. 18. Soft tissue point most antero-superior between Embrasure and Labial Inferioris. 19. Soft tissue point most antero-inferior between Embrasure and Labial Inferioris. 20. Labial Inferioris, anterior-most point on the lower lip. 21. Soft tissue point most antero-superior between Labial Inferioris and soft tissue B. 22. Soft tissue point most antero-inferior between Labial Inferioris and soft tissue B. 23. Soft tissue B, innermost point on the curve below the lower lip. 24. Soft tissue point most antero-superior between soft tissue B and soft Pogonion. 25. Soft Pogonion, anterior-most point on the chin on the aesthetic plane.

film was standardized to 8 per cent. For each cephalograph, x and y co-ordinates of 25 soft tissue landmarks (Figure 1) were digitized using appropriate software and a digitizing tablet (Rocky Mountain Orthodontics, USA). These landmarks encompassed the lateral facial profile and permitted the construction of the soft tissue matrices to be studied. For the x and y co-ordinates of the landmarks, the digitization error was less than 1 per cent on

duplicate digitization ($P > 0.05$). Therefore, the landmarks were deemed to be identified reliably.

To determine whether the prepubertal, pre-treatment and ≈ 13 month post-treatment soft tissue configurations differed, each pre-treatment mean geometry was compared statistically with the post-treatment mean geometry using ANOVA. Similarly, the adolescent, pre-treatment and ≈ 22 month post-treatment soft tissue mean geometries were compared statistically. As both cohorts were segregated into male and female groups, the mean geometries of each sex at each age were also compared. Therefore, four comparisons were generated in total. In all instances, the null hypothesis was that the pre- and post-treatment means were not significantly different.

For statistical analysis, a Procrustes method (Singh *et al.*, 1998) was employed to determine the variance around each landmark and express it as a root mean square. Therefore, each group was subjected to Procrustes superimposition and was represented as a mean and variance. The Procrustes routine was implemented on an Amiga 3000 computer, and an average geometry for each group was determined using a generalized orthogonal Procrustes analysis. Following this method, every object's co-ordinates were translated, rotated, and scaled iteratively until the least-squares fit of all configurations was no longer improved. Residuals and corresponding F values were computed, tabulated, and compared. Therefore, all configurations were registered with respect to one another, and as a result of this procedure, geometric configurations were scaled to equivalent areas, avoiding problems introduced by differences in size.

In order to demonstrate areas of soft tissue alteration, FESA was undertaken that incorporated a spline interpolation function. Based on this approach, differences can be described graphically as a size and/or shape change (Singh *et al.*, 1999a,b). The FESA software was written in 'C' and implemented on an Amiga 3000 computer. The mean, pre-treatment configuration was taken as the initial geometry, and this configuration was compared with the post-treatment mean. Size change variables were computed as the product of the principal extensions, while shape change measures were calculated as the ratio of the greater divided by the lesser principal extension. Deformation values were computed for at least 2000 points per geometry. For graphical display, a log-linear interpolation of the size and shape values

was used to generate a colour map. These form change measures were then colour-mapped into each pre-treatment configuration to provide graphical displays of geometric change for the particular comparison.

Results

Table 1 shows the results of the statistical analysis of mean pre- and post-treatment soft tissue matrices of patients treated using TBA. Statistical difference ($P < 0.001$) between the mean prepubertal, pre-treatment and ≈ 13 month post-treatment soft tissue configurations for both girls and boys was established using ANOVA. Statistical differences were also significant when comparing male and female adolescent, pre- and ≈ 22 month post-treatment mean soft tissue profiles ($P < 0.001$).

For prepubertal males, the overall soft tissue nodal mesh exhibited a positive allometry (size-related form change $\approx 20\%$). A conspicuous area in the labiomental groove, however, was localized with a positive allometry ≈ 25 per cent (Figure 2a). In contrast, the lips and mental region showed negative allometry ($\approx 5\%$ decrease in local size).

The prepubertal female configuration (Figure 2b) also showed positive allometry but this was less marked ($\approx 5\%$) than that found in the prepubertal male. Similar to the males, however, the area around the labiomental groove showed evidence of an increase in size ($\approx 6\%$), but the upper and lower lips and labial fissure showed negative allometry ($\approx 25\%$ decrease in local size).

For the adolescent males (Figure 2c), the configuration showed a marked overall positive allometry ($\approx 18\%$), localized particularly in the nasal and mental regions ($\approx 19\%$). Similar to the prepubertal configurations, the labiomental groove showed positive allometry ($\approx 18\%$) whereas the upper and lower lips showed negative allometry ($\approx 25\%$).

The adolescent female configuration (Figure 2d) showed a similar overall positive allometry ($\approx 17\%$). In contrast to the other configurations, the adolescent female circumoral region showed a positive allometry ($\approx 18\%$) slightly greater than that of the labiomental groove ($\approx 17\%$). However, similar to the other configurations, the upper lip decreased in size ($\approx 25\%$) whereas the lower lip and mental region also showed some negative allometry ($\approx 5\%$).

Table 1 Procrustes analysis of mean pre- and post-operative soft tissue configurations of subjects treated using Twin Block appliances.

	Prepubertal males	Prepubertal females	Pubertal males	Pubertal females
Residual	0.0007	0.0004	0.0006	0.0004
F value	1.014	1.242	1.745	1.086
P	<0.001	<0.001	<0.001	<0.001

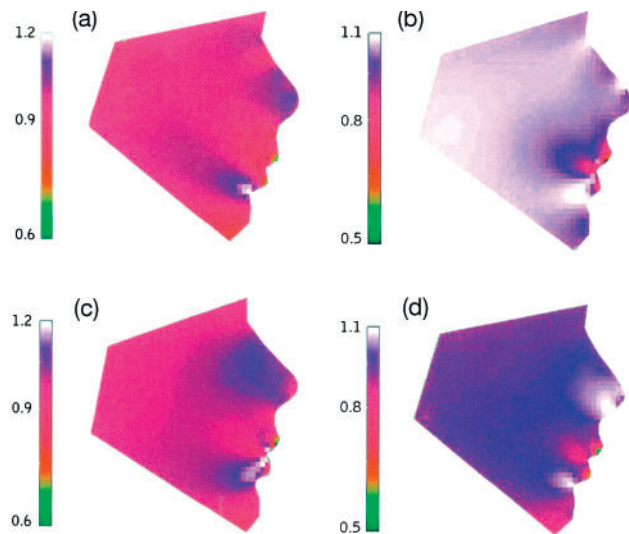


Figure 2 (a) Prepubertal male configuration. The soft tissue nodal mesh exhibits a generalized (purple-red) positive allometry ($\approx 20\%$). A conspicuous (white) area in the labiomental groove, however, has a positive allometry of ≈ 25 per cent. In contrast, the tips of the upper and lower lips and mental region show some negative allometry (green). (b) Prepubertal female configuration. The soft tissue nodal mesh shows generalized positive allometry (white-purple) of ≈ 5 per cent. The region of the labiomental groove (white) shows an increase in size ($\approx 6\%$), but the tips of the upper and lower lips and labial fissure (red) show negative allometry ($\approx 25\%$). (c) Pubertal male configuration. Note the red-purple colouration of the configuration, indicating a marked generalized positive allometry ($\approx 18\%$), localized particularly in the nasal region ($\approx 19\%$). The labiomental groove shows a white region of positive allometry ($\approx 18\%$) whereas the upper and lower lips and labial fissure show red areas of negative allometry ($\approx 25\%$). (d) Pubertal female configuration. Note the red-purple overall colouration of positive allometry ($\approx 17\%$). However, a white region of positive allometry ($\approx 18\%$) is found in the circumoral region, slightly greater than the purple region at the labiomental groove ($\approx 17\%$). The upper lip tip shows a green region, indicating decrease in size ($\approx 25\%$) whereas the lower lip and mental region also showed some red areas of negative allometry ($\approx 5\%$).

For shape change, all configurations studied were highly isotropic (uniform shape change) over the entire nodal mesh (Figure 3a–d). Minor anisotropy (directionality of shape change) was evident for prepubertal males at the labiomental groove ($\approx 2\%$), for prepubertal females at the labial fissure ($\approx 3\%$), for adolescent males at the labial fissure and labiomental groove ($\approx 3\%$), and for adolescent females at the labial fissure and near the labiomental groove ($\approx 3\%$).

Discussion

There are a number of morphometric techniques available for the study of form change, and in this study Procrustes superimposition and FESA were utilized. These techniques have their individual advantages and disadvantages. For example, superimposition-based

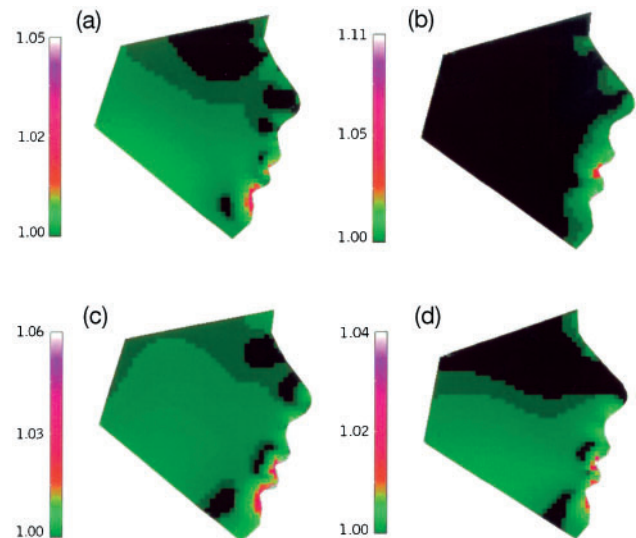


Figure 3 (a) Prepubertal male configuration. For shape change, the configuration studied is highly isotropic over the entire nodal mesh. Minor anisotropy (red-purple colouration) is evident at the labiomental groove ($\approx 2\%$). (b) Prepubertal female configuration. The soft tissue configuration is highly isotropic over the entire nodal mesh. There is minor anisotropy at the labial fissure ($\approx 3\%$), indicated by a red area. (c) Pubertal male configuration. For shape change, the soft tissue configuration is highly isotropic over the entire nodal mesh. There is minor anisotropy at the labial fissure and labiomental groove ($\approx 3\%$), indicated by the red colouration. (d) Pubertal female configuration. The soft tissue configuration is highly isotropic over the entire mandibular nodal mesh. There is minor anisotropy at the labial fissure and near the labiomental groove ($\approx 3\%$) as indicated by the red regions.

techniques attempt to recreate vectors that depict form change, commonly using the Procrustes distance as a measure of proximity of landmarks, but there are many different measures of proximity and corresponding superimposition methods. Despite these limitations, the FESA used in the present study was able to localize and quantify soft tissue changes associated with TBA treatment.

Greater emphasis is being placed on soft tissue examination during clinical diagnosis and planning (Ackerman *et al.*, 1999) and, although the present investigation is restricted to two dimensions, it has been noted that 3D soft tissue measurements can be correlated with cephalometric data (Ferrario *et al.*, 1996a). However, it has also been suggested that traditional cephalometry of ideal soft tissue contour may yield data of dubious scientific and clinical value (Lavelle and Carvalho, 1989), and that shape similarities can largely be overwhelmed by size differences (Ferrario *et al.*, 1995b). Therefore, in the assessment of facial form and form change, rigorous analysis of shape and size change is appropriate. Geometric morphometric techniques of investigation, such as FESA, permit decomposition of morphological integration (Richtsmeier and Cheverud,

1986). Details of the FESA technique used in this study have been reported earlier (Singh and Clark, 2001) and will not be repeated here. Nevertheless, the application of FESA is warranted in the analysis of craniofacial growth and development (e.g. Cangialosi *et al.*, 1994).

It has been suggested that there is only modest sexual dimorphism of craniofacial structures present at prepubertal ages (Riolo *et al.*, 1974). In a 3D soft tissue study, however, sexual dimorphism in the timing of facial growth was reported (Ferrario *et al.*, 1998a). While it is noted that soft tissue linear distances are significantly larger in boys (Ferrario *et al.*, 1999), exceptions are due to the earlier female growth spurt, and in the 3D morphometry of adult cutaneous facial landmarks no significant sex differences were found (Ferrario *et al.*, 1996b). In accordance with this hypothesis, in the current study it was found that prepubertal boys showed an overall larger increase in soft tissue size compared with prepubertal girls, but an overall dissimilarity in the male and female adolescent nose and chin regions was demonstrable. In terms of sexual dimorphism, the prepubertal boys showed positive soft tissue allometry in the nasal region ($\approx 10\%$), but the mental region showed no increase in local size, as the adolescent growth spurt had not yet commenced. Similarly, while the prepubertal girls showed positive allometry this, as might be expected, was less marked than that found in the prepubertal boys (Ferrario *et al.*, 1999). Thus, given the pubertal growth spurt, the magnitude of size change was greater in adolescents than in younger children. Also, while TBA treatment may be associated with improved skeletal relations and facial aesthetics, sexual dimorphism in the nasal and mental regions was evident, particularly in the adolescent males (Figure 2c).

It has been indicated that during the adolescent growth spurt, soft tissue changes emphasize the nose and chin more prominently (Kess, 1990). In line with this suggestion, it was also noted in the present study that the nose becomes more prominent in adolescent males. For the adolescent males, there was marked positive allometry, localized particularly in the nasal region and chin ($\approx 20\%$). The adolescent females showed similar overall positive allometry but the mental region demonstrated less change compared with the adolescent males. These findings verify the sexual dimorphism in the timing of facial growth in male and female soft tissues (Ferrario *et al.*, 1998a). Nevertheless, developmental independence of hard and soft tissue matrices (Park and Burstone, 1986) suggests that careful evaluation of the soft tissue drape together with the underlying hard tissue structure is needed (Ferrario *et al.*, 1998b). This suggestion reflects those of an earlier study that showed increased projection of the nose in untreated cases (Genecov *et al.*, 1990), even though the relationship of

the nose, lips, and chin remained relatively independent of the underlying skeletal growth. Indeed, an analysis of the bony midface determined that the maxillary complex exhibits a posterior translation during TBA treatment (Singh and Hodge, 2002).

In Class II cases, lower lip eversion and trapping below the upper incisors is often noted. It has been suggested that TBA treatment may produce a rapid but stable change in facial appearance. In this current study using FESA, the crests of the upper and lower lips invariably showed a decrease in local size. This alteration reflects a reduction in overjet, by incisor tipping and bodily correction thought to be produced by functional appliances (Trenouth, 1992). The reduced overjet with concomitant functional improvements could provide a more effective anterior lip seal. Indeed, it has been suggested that the soft tissue response to TBA treatment assists mastication and swallowing by providing a more effective anterior oral seal, which is maintained and is claimed to improve facial balance (Clark, 1982, 1988). In this study a flattening of the labiomental groove following TBA treatment was demonstrable, perhaps reflecting improvement of the underlying dental, dento-alveolar, and/or symphyseal morphology.

A tendency for males to continue growth later than females (a large part of male facial volume increase occurring in the lower third of the face) has been suggested (Ferrario *et al.*, 1998c). Not surprisingly, perhaps, it was noted in the present study that the prepubertal male and adolescent female configurations exhibited less allometry in the mental region, representing dichotomy in the timing of mandibular growth, and sexual dimorphism, when compared with the adolescent male. It has also been suggested that sexual differences are evident in facial size but not shape (Ferrario *et al.*, 1998d). In line with those assertions, a high degree of isotropy over the soft tissue nodal mesh with only minor degrees of anisotropy in restricted areas was demonstrated in the present study. However, in an investigation of facial features, 3D morphometry was unable to determine attractiveness (Ferrario *et al.*, 1997b). As Angle Class II children have an increased facial convexity and a less prominent mandibular soft tissue complex compared with children with a normal occlusion, it appears that TBA treatment reduces facial convexity. It is concluded that this outcome is reached by improving the underlying mandibular discrepancy, with dental and dento-alveolar improvements, and associated correction of lip form and function. Nevertheless, it is impossible to specifically discretize normal growth from changes associated with TBA treatment. Further studies using 3D digital surface rendering and geometric growth analyses are currently being undertaken to determine whether the improvements noted in this study are maintained long-term.

Address for correspondence

Dr G. D. Singh
Office A-570
School of Medicine
University of Puerto Rico
PO Box 365067
San Juan, PR 00936-5067, USA

References

- Ackerman J L, Proffit W R 1997 Soft tissue limitations in orthodontics: treatment planning guidelines. *Angle Orthodontist* 67: 327–336
- Ackerman J L, Proffit W R, Sarver D M 1999 The emerging soft tissue paradigm in orthodontic diagnosis and treatment planning. *Clinical Orthodontics and Research* 2: 49–52
- Al Yami E A, Kuijpers-Jagtman A M, Van 't Hof M A 1998 Assessment of dental and facial aesthetics in adolescents. *European Journal of Orthodontics* 20: 399–405
- Blanchette M E, Nanda R S, Currier G F, Ghosh J, Nanda S K 1996 A longitudinal cephalometric study of the soft tissue profile of short- and long-face syndromes from 7 to 17 years. *American Journal of Orthodontics and Dentofacial Orthopedics* 109: 116–131
- Cangialosi T J, Moss M L, McAlarney M E, Nirenblatt B D, Yuan M 1994 An evaluation of growth changes and treatment effects in Class II, division 1 malocclusion with conventional roentgenographic cephalometry and finite element method analysis. *American Journal of Orthodontics and Dentofacial Orthopedics* 105: 153–60
- Clark W J 1982 The Twin Block traction technique. *European Journal of Orthodontics* 4: 129–138
- Clark W J 1988 The Twin Block technique: a functional orthopedic appliance system. *American Journal of Orthodontics and Dentofacial Orthopedics* 93: 1–18
- Ferrario V F, Sforza C 1997 Size and shape of soft-tissue facial profile: effects of age, gender, and skeletal Class. *Cleft Palate-Craniofacial Journal* 34: 498–504
- Ferrario V F, Sforza C, Serrao G, Puletto S, Bignotto M, Tartaglia G 1994 Comparison of soft tissue facial morphometry in children with Class I and Class II occlusions. *International Journal of Adult Orthodontics and Orthognathic Surgery* 9: 187–194
- Ferrario V F, Sforza C, Poggio C E, Tartaglia G 1995a Facial morphometry of television actresses compared with normal women. *Journal of Oral and Maxillofacial Surgery* 53: 1008–1014
- Ferrario V F, Sforza C, Schmitz J H, Miani A Jr, Taroni G 1995b Fourier analysis of human soft tissue facial shape: sex differences in normal adults. *Journal of Anatomy* 187: 593–602
- Ferrario V F, Sforza C, Puleo A, Poggio C E, Schmitz J H 1996a Three-dimensional facial morphometry and conventional cephalometrics: a correlation study. *International Journal of Adult Orthodontics and Orthognathic Surgery* 11: 329–338
- Ferrario V F, Sforza C, Poggio C E, Serrao G 1996b Facial three-dimensional morphometry. *American Journal of Orthodontics and Dentofacial Orthopedics* 109: 86–93
- Ferrario V F, Sforza C, Miani Jr A, Pizzini G 1997a A size-standardized analysis of soft tissue facial profile during growth. *American Journal of Orthodontics and Dentofacial Orthopedics* 112: 28–33
- Ferrario V F, Sforza C, Poggio C E, Colombo A, Tartaglia G 1997b The relationship between facial 3-D morphometry and the perception of attractiveness in children. *International Journal of Adult Orthodontics and Orthognathic Surgery* 12: 145–152
- Ferrario V F, Sforza C, Poggio C E, Schmitz J H 1998a Craniofacial growth: a three-dimensional soft-tissue study from 6 years to adulthood. *Journal of Craniofacial Genetics and Developmental Biology* 18: 138–149
- Ferrario V F, Sforza C, Serrao G, Colombo A, Ciusa V, Bignotto M 1998b Reliability of soft tissue references for anteroposterior measurement of dental bases. *International Journal of Adult Orthodontics and Orthognathic Surgery* 13: 210–216
- Ferrario V F, Sforza C, Poggio C E, Schmitz J H 1998c Facial volume changes during normal human growth and development. *Anatomical Record* 250: 480–487
- Ferrario V F, Sforza C, Schmitz J H, Miani A Jr, Serrao G 1998d A three-dimensional computerized mesh diagram analysis and its application in soft tissue facial morphometry. *American Journal of Orthodontics and Dentofacial Orthopedics* 114: 404–413
- Ferrario V F, Sforza C, Poggio C E, Schmitz J H 1999 Soft-tissue facial morphometry from 6 years to adulthood: a three-dimensional growth study using a new modeling. *Plastic and Reconstructive Surgery* 103: 768–778
- Foley T F, Duncan P G 1997 Soft tissue profile changes in late adolescent males. *Angle Orthodontist* 67: 373–380
- Genecov J S, Sinclair P M, Dechow P C 1990 Development of the nose and soft tissue profile. *Angle Orthodontist* 60: 191–198
- Giddon D B 1995 Orthodontic applications of psychological and perceptual studies of facial esthetics. *Seminars in Orthodontics* 1: 82–93
- Jacobson A 1984 Psychological aspects of dentofacial esthetics and orthognathic surgery. *Angle Orthodontist* 54: 18–35
- Kess K 1990 Age-dependent soft-tissue changes in the face. *Fortschritte der Kieferorthopädie* 51: 373–377
- Lavelle C L, Carvalho R S 1989 An evaluation of the changes in soft-tissue profile form induced by orthodontic therapy. *American Journal of Orthodontics and Dentofacial Orthopedics* 96: 467–476
- Morris D O, Illing H M, Lee R T 1998 A prospective evaluation of Bass, Bionator and Twin Block appliances. Part II: the soft tissues. *European Journal of Orthodontics* 20: 663–684
- Moss J P, McCance A M, Fright W R, Linney A D, James D R 1994 A three-dimensional soft tissue analysis of fifteen patients with Class II, division 1 malocclusions after bimaxillary surgery. *American Journal of Orthodontics and Dentofacial Orthopedics* 105: 430–437
- Park Y C, Burstone C J 1986 Soft-tissue profile; fallacies of hard-tissue standards in treatment planning. *American Journal of Orthodontics and Dentofacial Orthopedics* 90: 52–62
- Richtsmeier J T, Cheverud J M 1986 Finite element scaling analysis of human craniofacial growth. *Journal of Craniofacial Genetics and Developmental Biology* 6: 289–323
- Riolo M L, Moyers R E, McNamara J A, Hunter W S 1974 An atlas of craniofacial growth. Monograph No. 2 Craniofacial Growth Series, Center for Human Growth and Development, University of Michigan, Ann Arbor
- Rondeau B 1996 Twin Block appliance. Part II. *Functional Orthodontist* 13: 4–16
- Singh G D, Clark W J 2001 Localization of mandibular changes in patients with Class II division 1 malocclusions treated using Twin Block appliances: finite-element modeling. *American Journal of Orthodontics and Dentofacial Orthopedics* 119: 419–425
- Singh G D, McNamara Jr J A, Lozanoff S 1998 Mandibular morphology in subjects with Angle's Class III malocclusion: finite-element morphometry. *Angle Orthodontist* 68: 409–418
- Singh G D, McNamara Jr J A, Lozanoff S 1999a Finite element morphometry of soft tissues of prepubertal Korean and European-Americans with Class III malocclusions. *Archives of Oral Biology* 44: 429–436
- Singh G D, McNamara Jr J A, Lozanoff S 1999b Finite-element morphometry of soft tissue morphology in subjects with untreated Class III malocclusions. *Angle Orthodontist* 69: 215–224
- Singh G D, Hodge M R 2002 Bimaxillary morphometry of patients with Class II division 1 malocclusion treated with Twin Block appliances. *Angle Orthodontist* 72: 402–409
- Trenouth M J 1992 A comparison of Twin Block, Andresen and removable appliances in the treatment of Class II division 1 malocclusion. *Functional Orthodontist* 9: 26–31